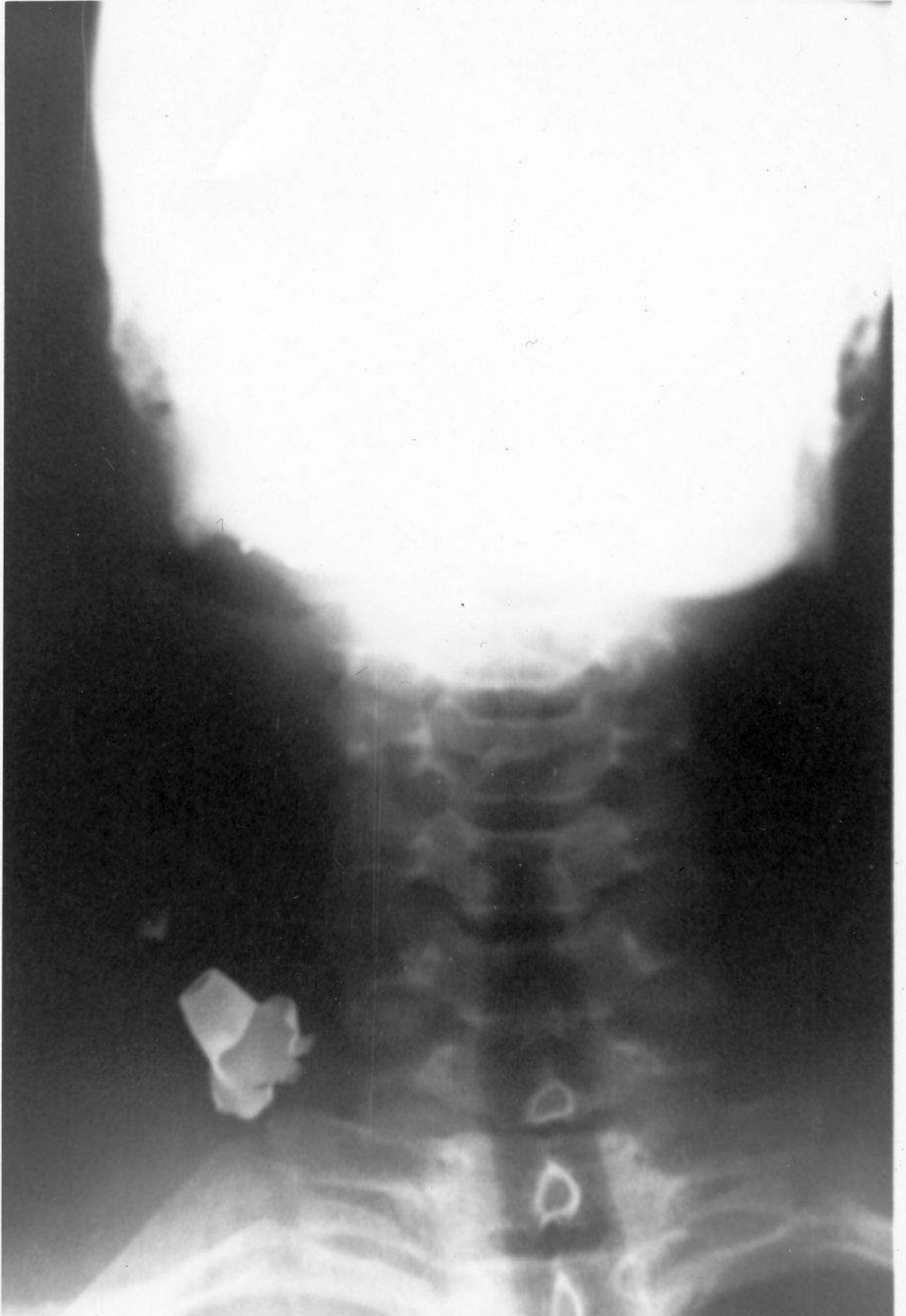
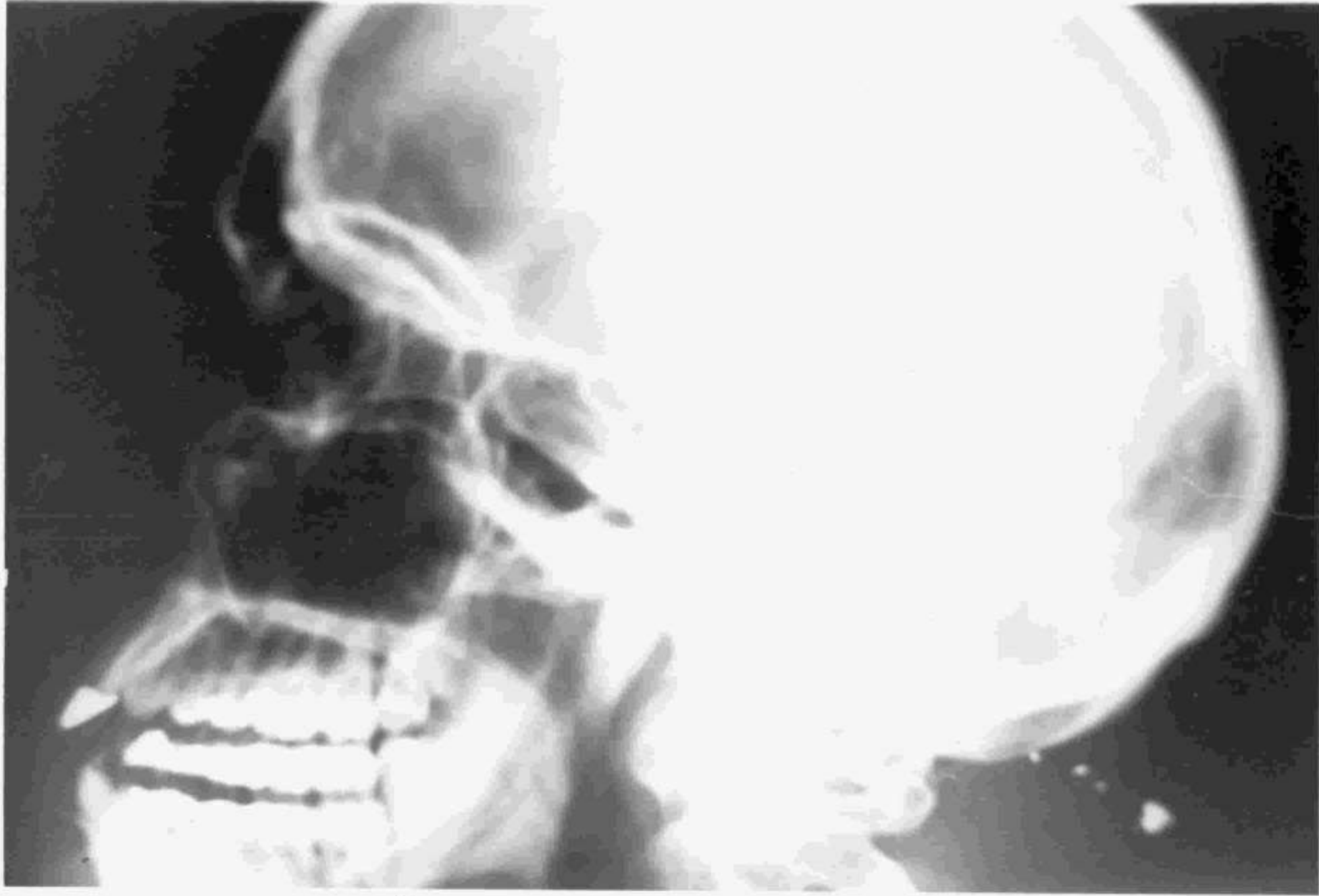
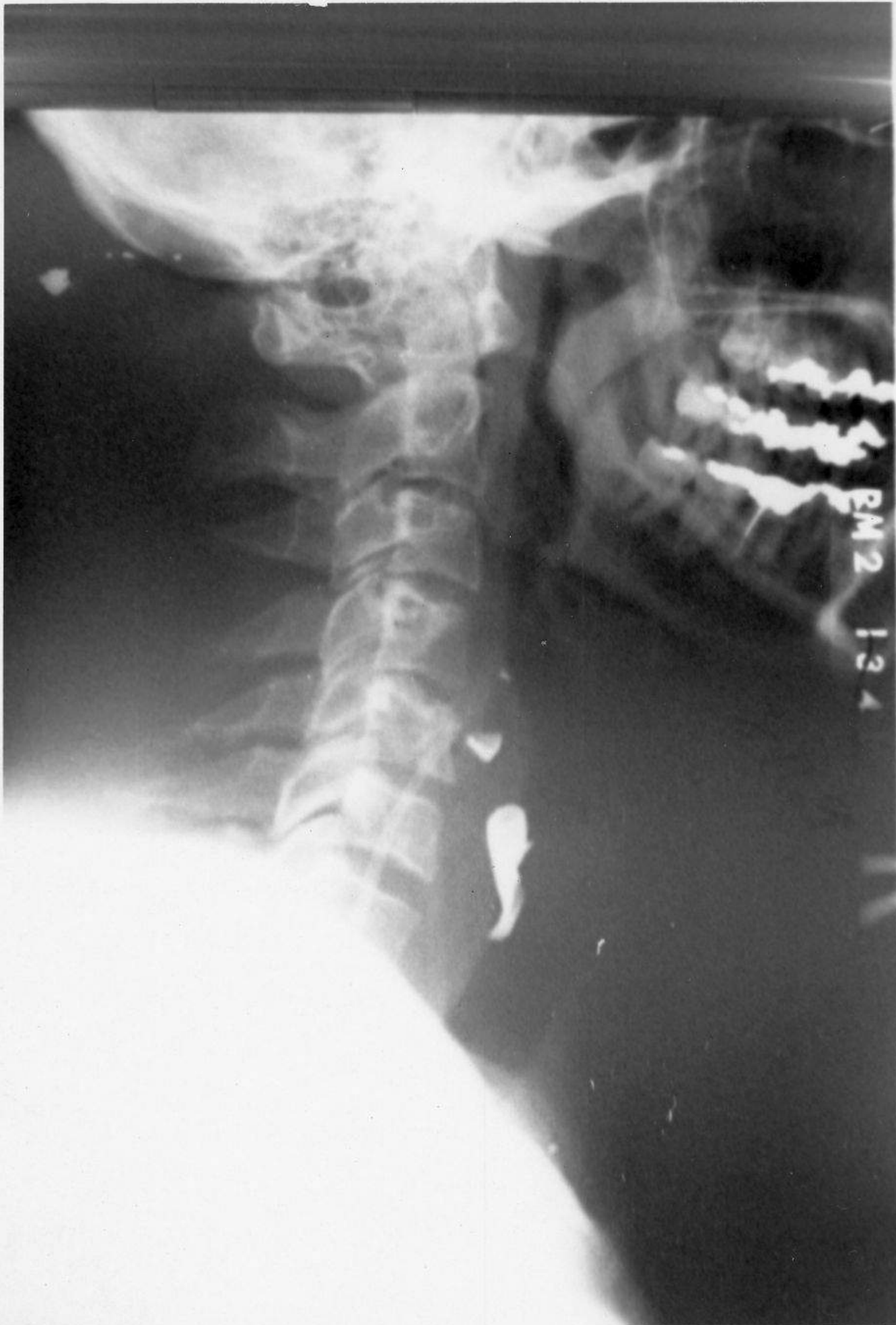
Below are three x-rays taken in Vietnam, two 2007 CT scans, and eight 2023 CT scans of Per-Olof Odmon's skull and neck. The second 2007 CT scan shows what he thought were ten pieces of shrapnel in his brain, but the shrapnel are actually in his neck. The second 2023 CT scans show the nine pieces of shrapnel in his neck, seen from above and behind.

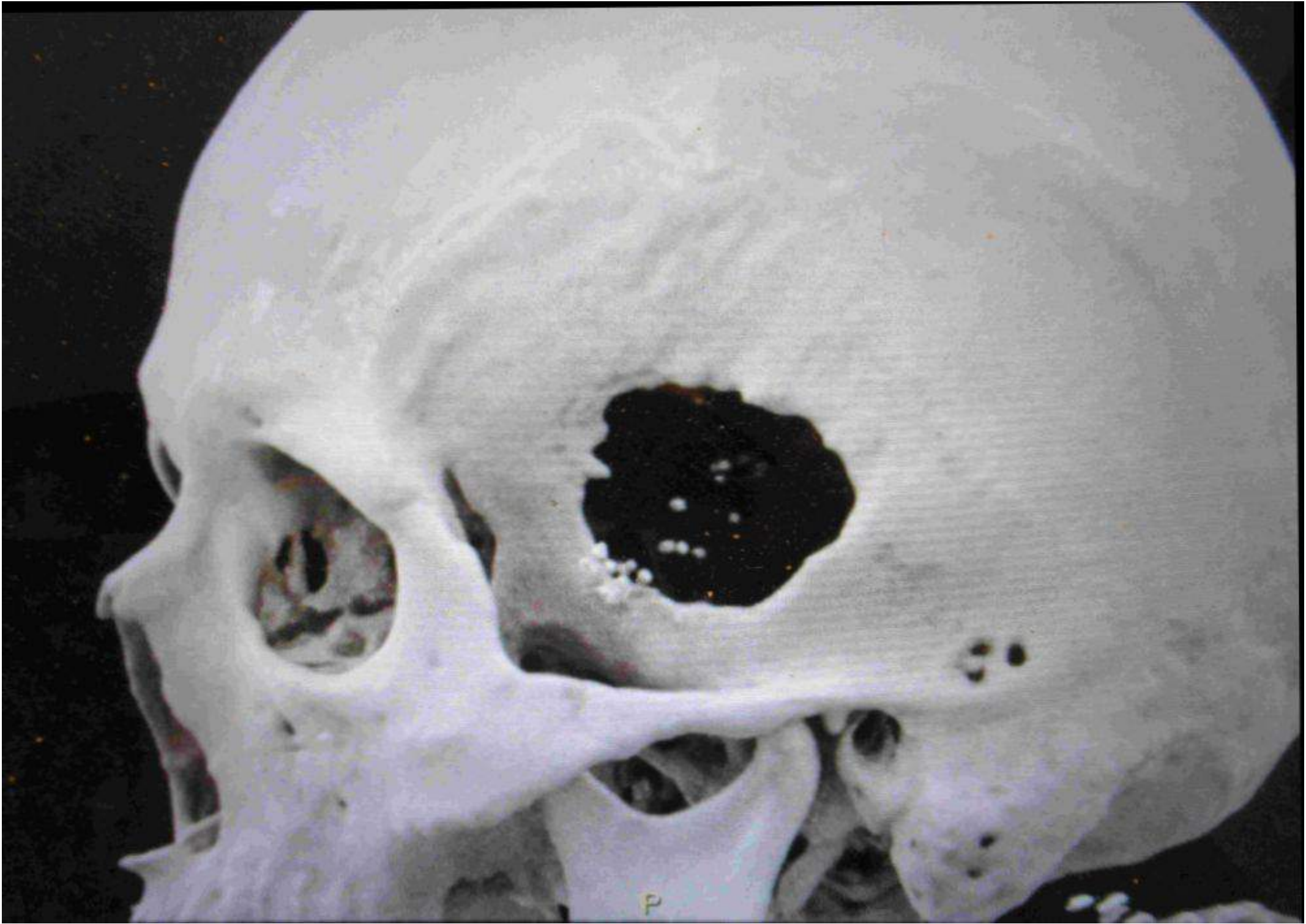



• JAN • 69 • ©

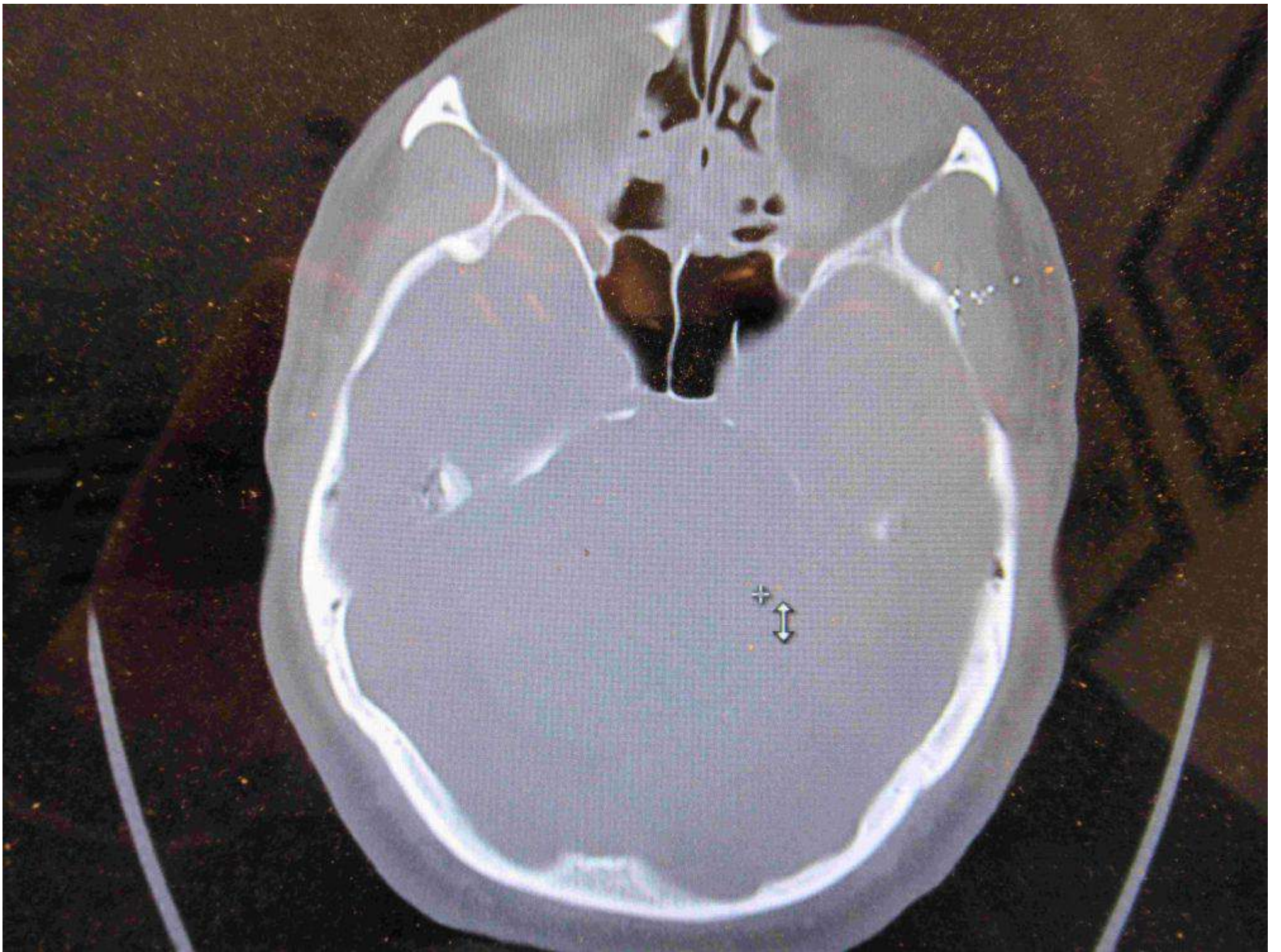


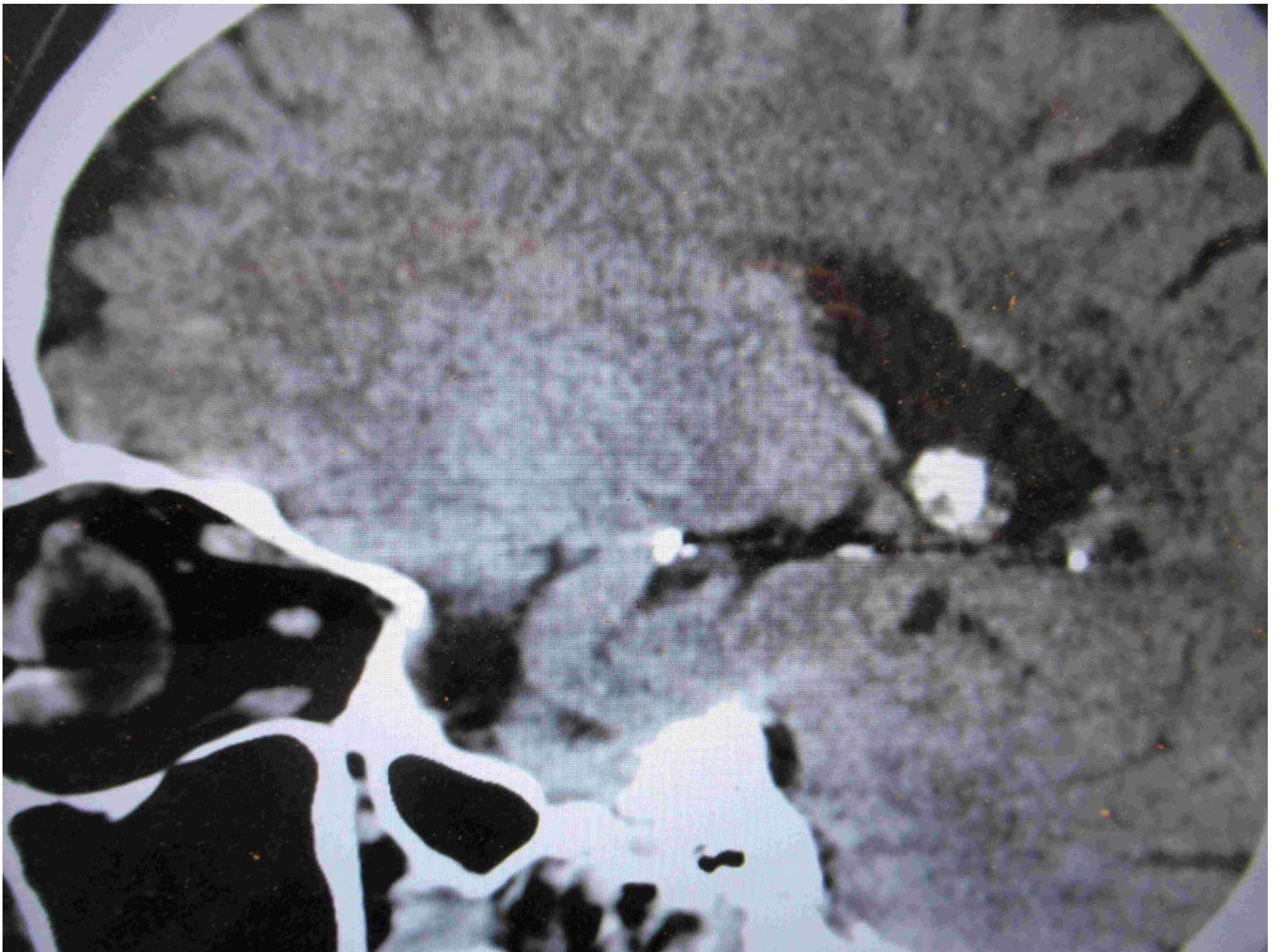


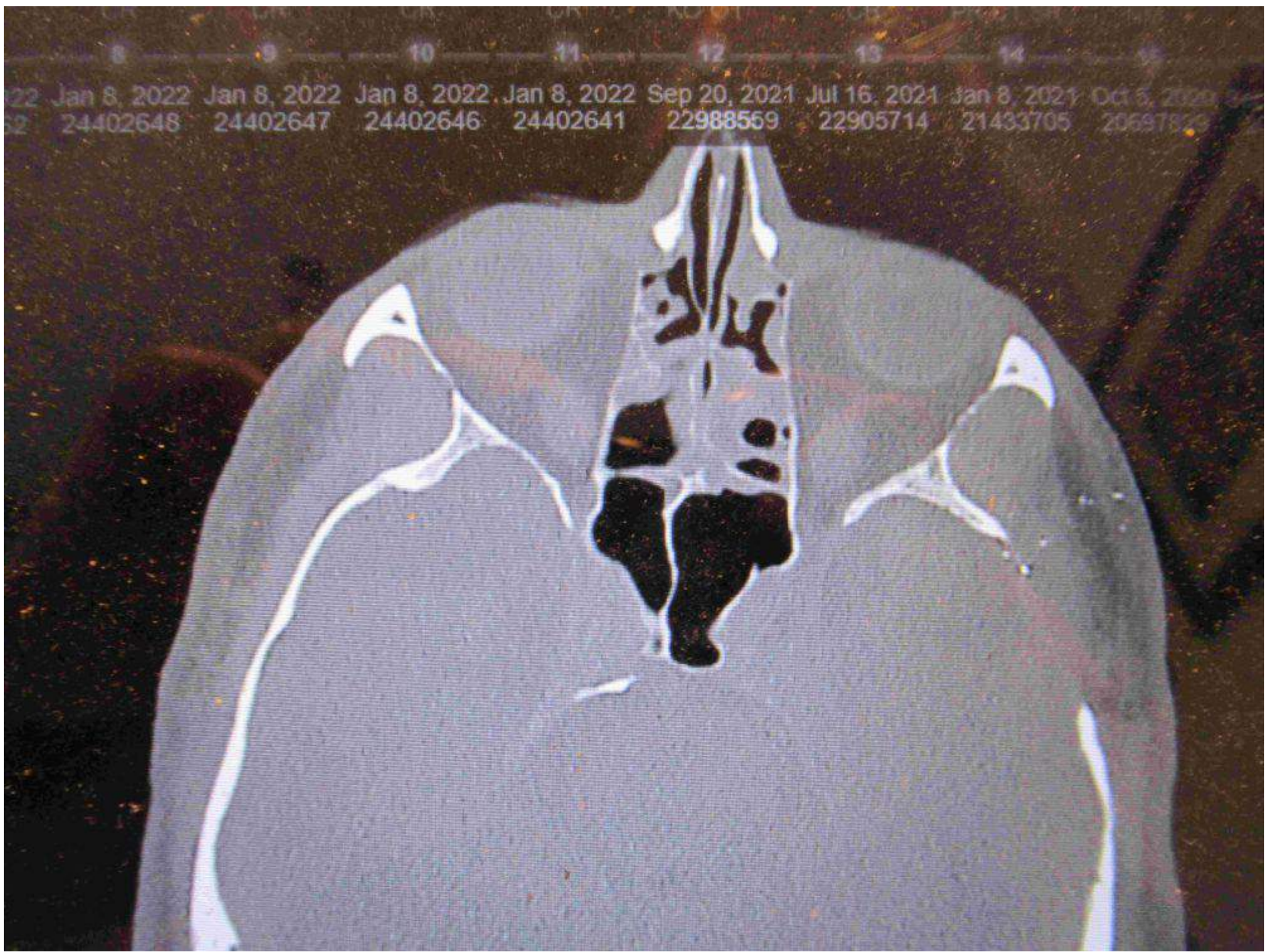
PM 2 124



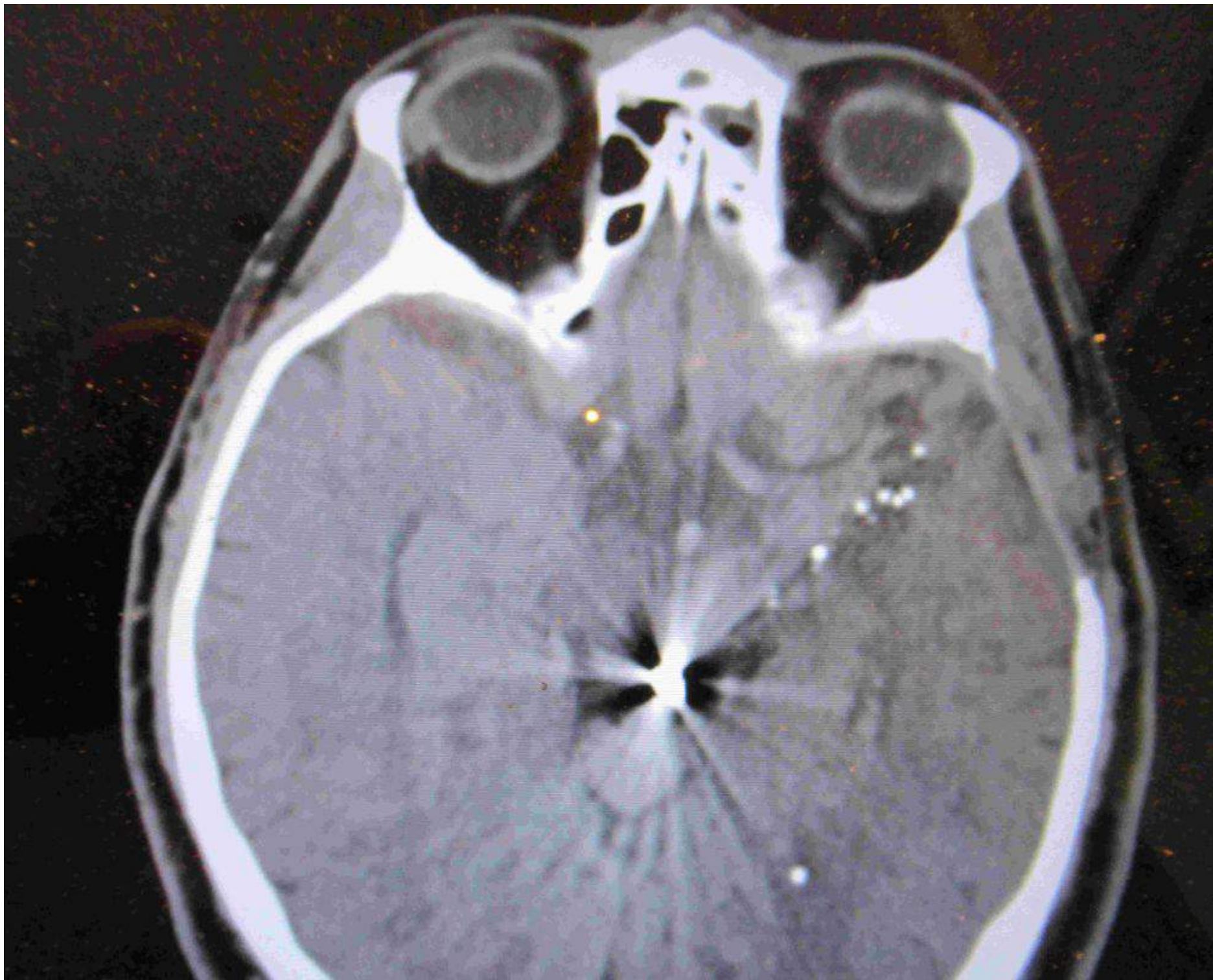


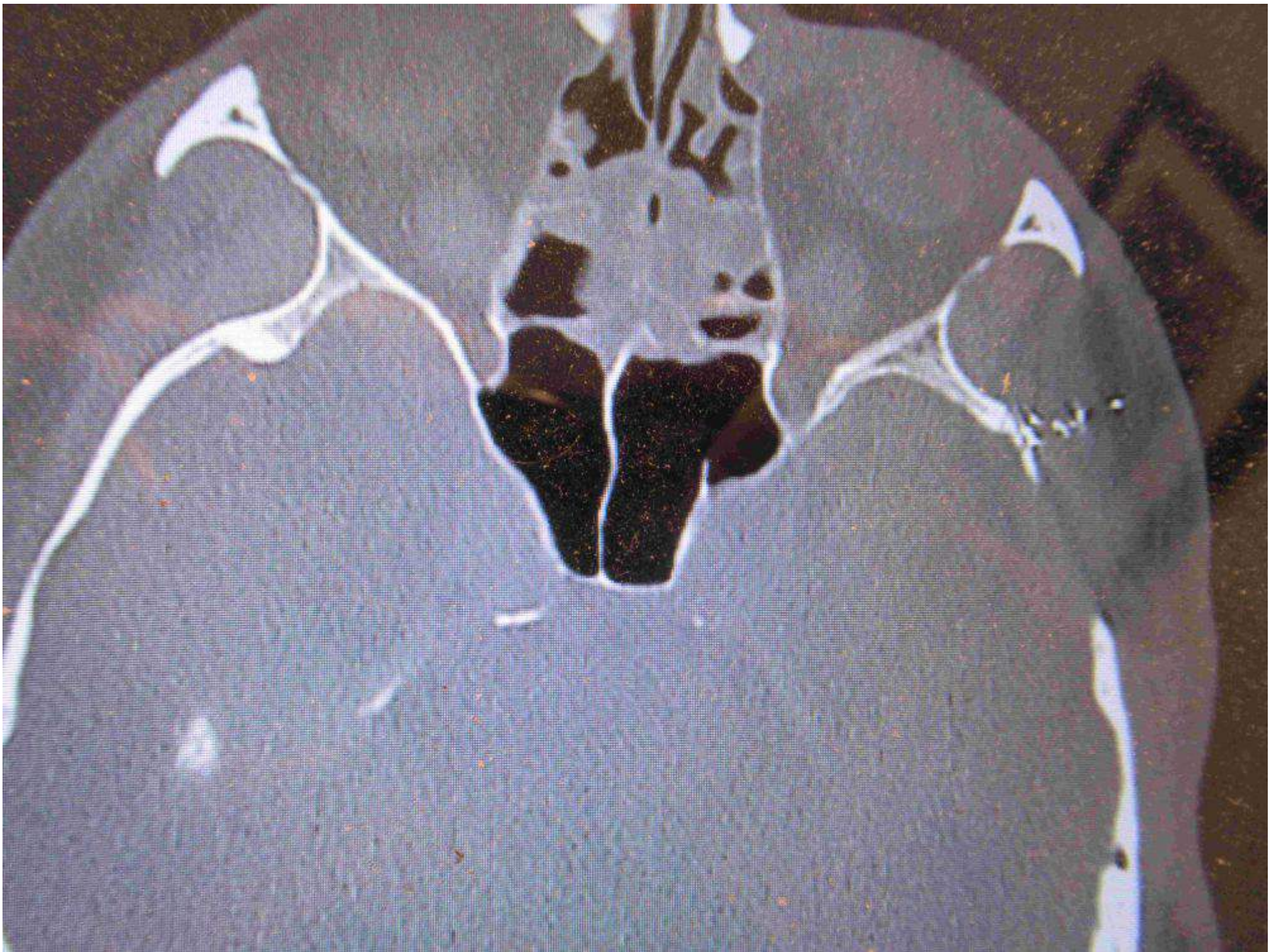

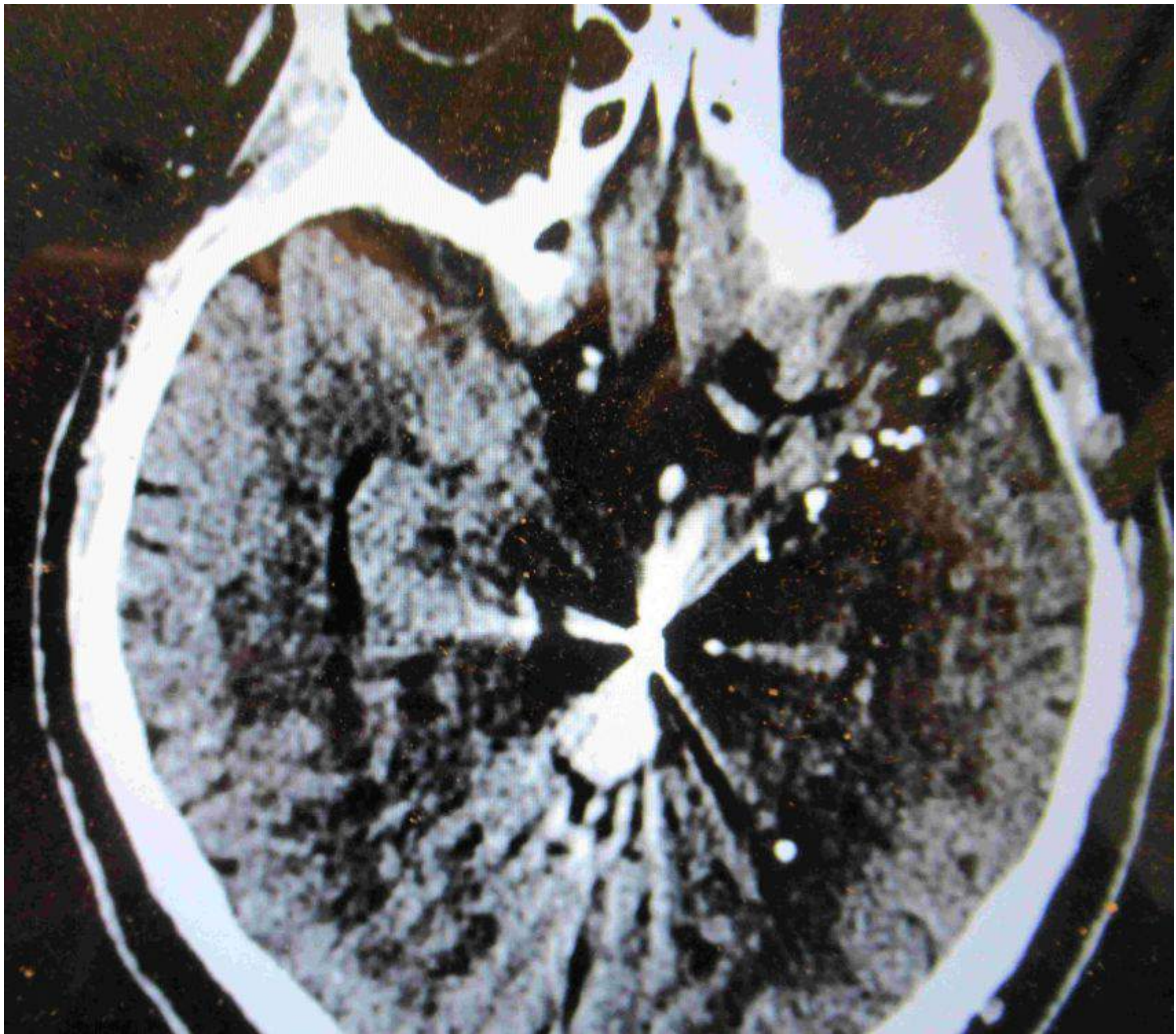




8 9 10 11 12 13 14 15
22 Jan 8, 2022 Jan 8, 2022 Jan 8, 2022 Jan 8, 2022 Sep 20, 2021 Jul 16, 2021 Jan 8, 2021 Oct 3, 2020
52 24402648 24402647 24402646 24402641 22988559 22905714 21433705 20697829







50
250
ulion
57
2000
2 11
mm
0

P

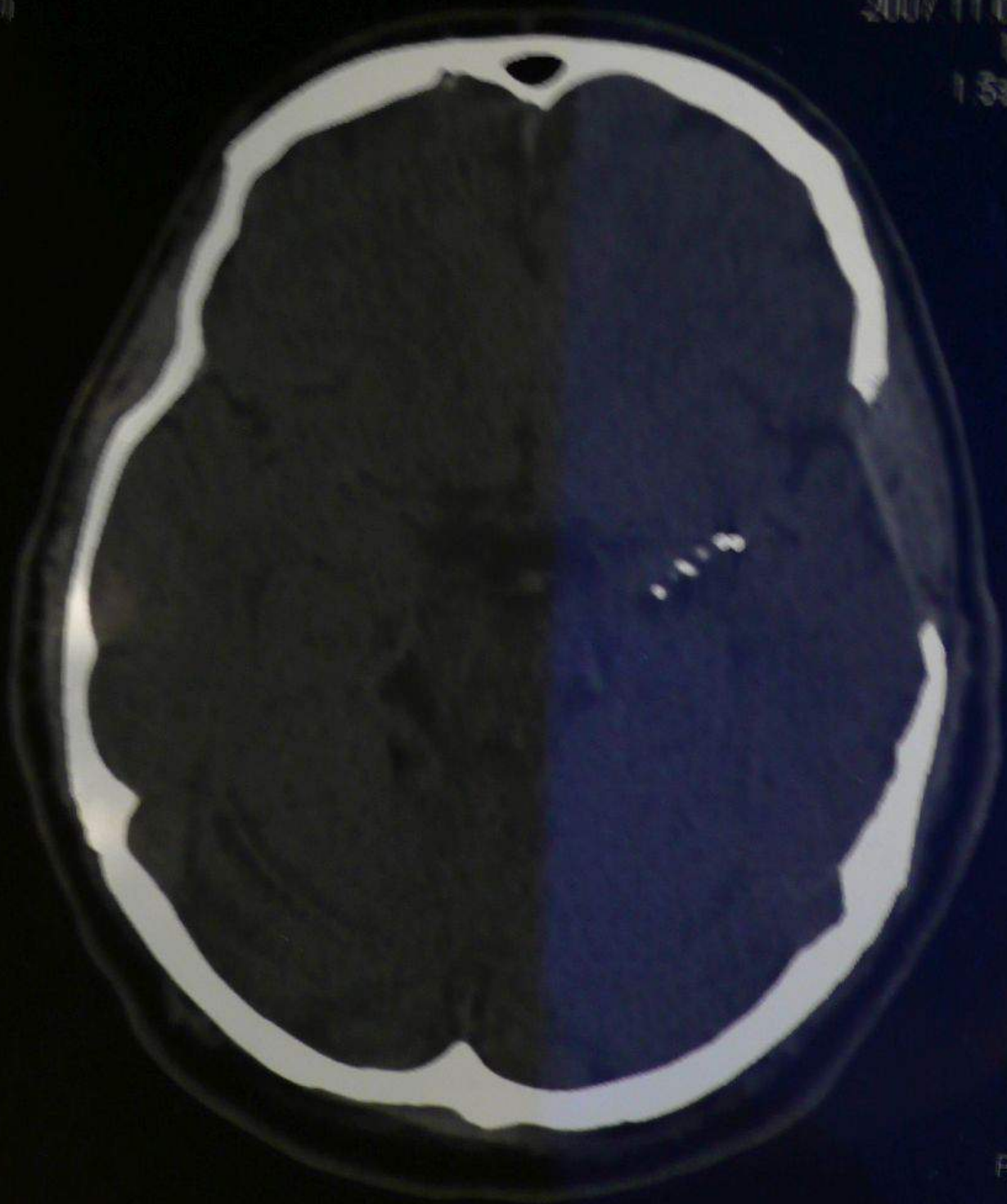
PROF. RADIOLOGY SERVICES

ODMAN PER-OLG

2007.11.06 10:40:39

120kV 37

1.5x4 0mm



P

PROF. RADIOLOGY SERVICES

ODMAN PER-OLG R.

2007.11.06 10:40:39 600

120kV 250mAs

1.0x1.0

ODMAN PER-OL

2007.11.08 10:40

120kV/2

1.5s/4 0mm

11
7660
lion

P

RIO S
631
SUNHE/M
FC300U
PROF. RADIOLOGY SERVICE
ODMAN PER-OL
2007.11.08 10:40

